

RAINBOW HOSPITAL FOR WOMEN AND CHILDREN
234, Old MLA Quarters Rd.
Banayalnagar, Hyderabad -500029
T - 040-48873000

Reg No (Under PC & PNDD Act 1994): 0116A1466/2023

FetalMedicine ID:
HNR2835286
ViewPoint ID: 2835286
Date 05-05-2026

Growth Scan

RAINBOW HOSPITAL
234/234, Old MLA
Banayalnagar, Hyderabad -500029
T - 040-48873000

Patient: Beerla Anjali DOB: 02-06-1996
Banayalnagar, hyd
Exam date: 05-05-2026

Indication Fetal growth scan

History **General** Smoking: no. Height 159 cm, 5 ft 3 in
History
OB History Gravida 1

Method Transabdominal ultrasound examination, Voluson E8. View: Suboptimal view: limited by late gestational age

Pregnancy Singleton pregnancy. Number of fetuses: 1

Dating	Date	Details	Gest. age	EDD
LMP	01-10-2025		30 w + 6 d	08-07-2026
Agreed dating	based on ultrasound (CRL)		30 w + 1 d	13-07-2026

General Evaluation Cardiac activity present. FHR 167 bpm. Fetal movements: visualised. Presentation: cephalic

Placenta: anterior high

Umbilical cord: 3 vessel cord

Amniotic fluid: Amount of AF: lower limit of normal. Largest pool 3.8 cm. AFI 8.5 cm

Fetal Biometry	Measurement	Value	Percentile	Measurement	Value	Percentile
BPD	77.1 mm	84%	TAD	82.2 mm		
OFD	95.9 mm	14%	AC	252.9 mm	26%	
HC	272.6 mm	20%	Femur	60.8 mm	76%	
Cerebellum tr	36.9 mm	88%	Humerus	51.4 mm	52%	
APAD	78.8 mm		HC / AC	1.08		

Fetal Weight Calculation:

EFW 1,548 g 43% EFW by Hadlock (BPD-HC-AC-FL)
EFW (lb,oz) 3 lb 7 oz

Head / Face / Neck Biometry:

BPD / OFD 0.80 63% 2nd Ventr 2.8 mm
1st Ventr 3.4 mm

Abdomen Biometry:

MAD 80.5 mm Trunk area 64.8 cm² 93%
Trunk area 50.9 cm² 147%

Urinary Tract Biometry:

Rt Renal pelvis ap 2.7 mm

Lt Renal pelvis ap 2.0 mm

Extremities / Bony Structures Biometry:

FL / BPD 0.79
FL / HC 0.22

FL / AC 0.24

Fetal Anatomy Face: could not be examined due to unfavourable fetal position..

The following structures were visualised:

Cranium. Brain. Heart. Abdominal wall. Spine.

Fetal Doppler

Umbilical Artery:

PI 1.16



85%

RI

0.71



83%

Mid Cerebral Artery:

PI 1.33



5%

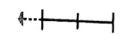
PS

0.86 MoM

PS 35.00 cm/s

CPR PI

1.15



<1%

Maternal Doppler

Right uterine artery:

PI 0.28



<1%

RI

0.22

Left uterine artery:

PI 0.71




34%

RI

0.47

Mean PI 0.50



3%

Comment

Please note: All fetal anomalies cannot be detected by ultrasound alone. The pick up rate of abnormalities depend on gestational age of the fetus, fetal position, maternal habitus, tissue penetration of ultrasound waves and machine resolution. The results of the today's scan have been discussed with the parents. They were aware that ultrasound examination alone cannot exclude all genetic syndromes or chromosomal abnormalities. This report is not for medicolegal purposes.

Impression

GDM on OHA

There is a single viable intrauterine pregnancy.

The fetus is in cephalic presentation today .

Fetal growth, (EFW - 43 rd centile)

Amniotic fluid (AFI - 8.5) - lower limit of normal

Fetal Doppler and Uterine artery Doppler are normal.

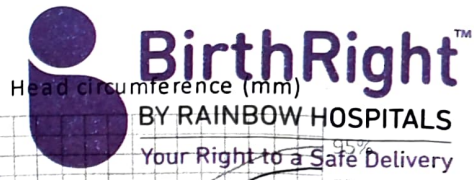Detailed structural evaluation of fetus not possible due to advanced gestation and fetal position. All abnormalities cannot be excluded by ultrasound alone. Some abnormalities evolve as gestational age advances.

Advice:

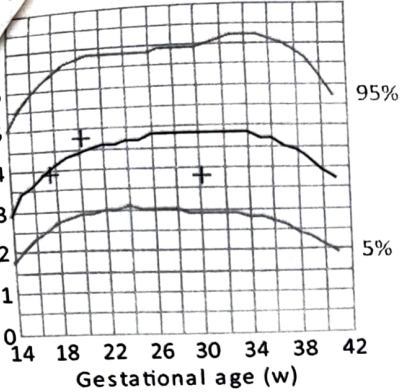
1. Rescan after 1 week for AFI (12 th may 2026)
2. To monitor fetal kick count and report to the hospital in case of reduced fetal movements.

I, Dr. Mythreyi. K declare that while conducting ultrasonography / image scanning on Mrs. Anjali, I have neither detected nor disclosed the sex of her fetus to any body in any manner.

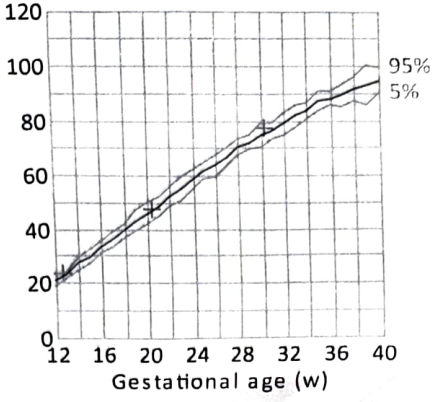
Medicine Report



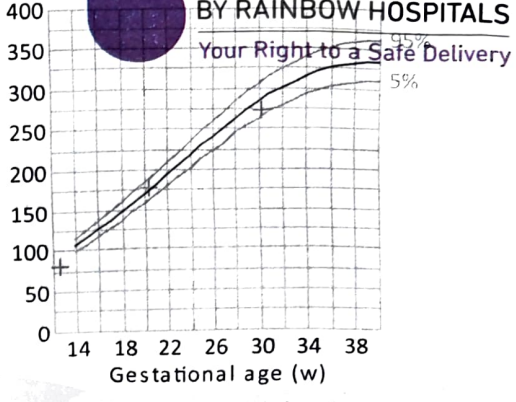
AF largest pool (cm)



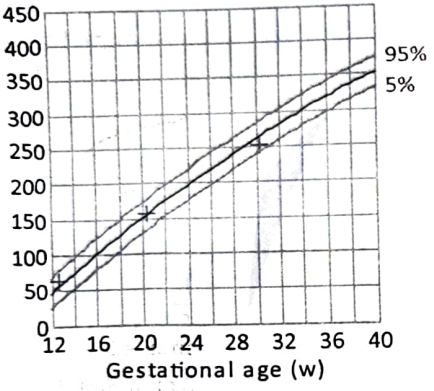
Biparietal diameter (mm)



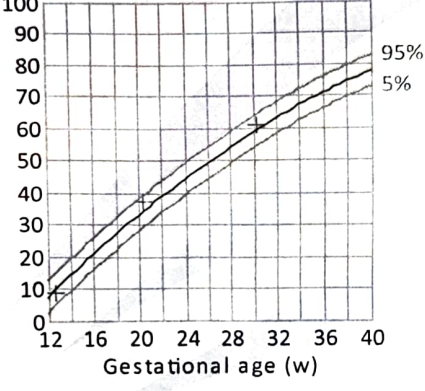
Head circumference (mm)



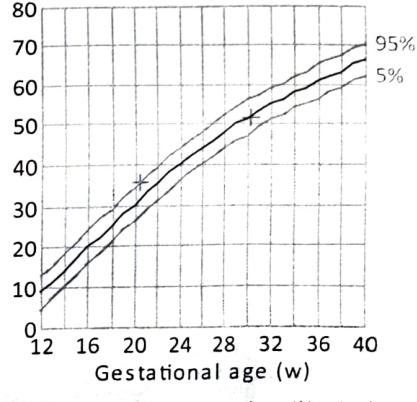
Abdominal circumference (mm)



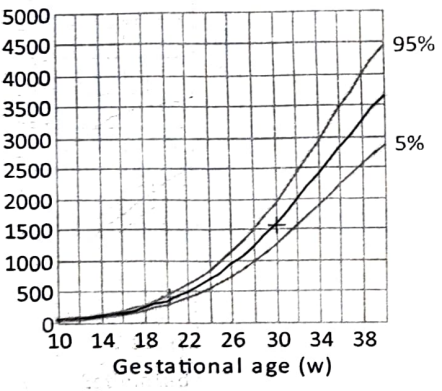
Femur length (mm)



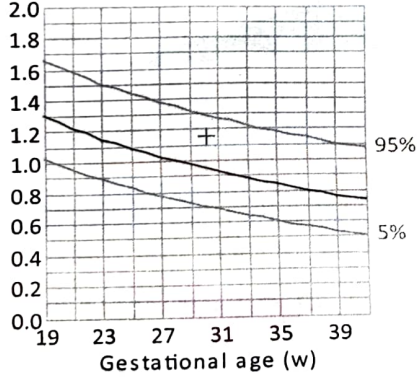
Humerus length (mm)



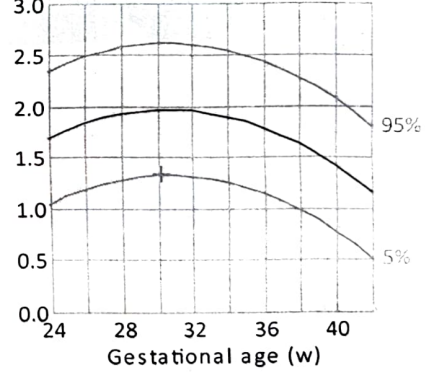
Estimated fetal weight (g)



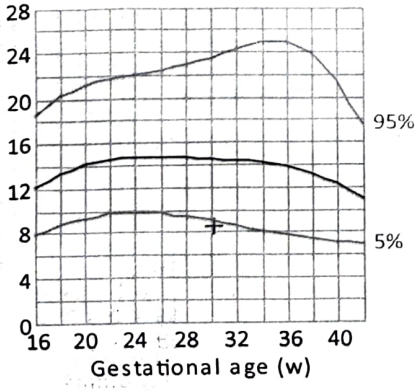
Umbilical artery pulsatility index



Mid cerebral artery pulsatility index



Amniotic Fluid Index (cm)



Dr. Indira Rani Y
Referring

Dr. Mythreyi K
Performing Physician

Rainbow Children's Medicare Limited

