



భారత విశిష్ట గుర్తింపు ప్రాధికార సంస్థ

భారత ప్రభుత్వం

Unique Identification Authority of India  
Government of India

నమోదు సంఖ్య / Enrollment No. : 1067/43014/01153

03/04/2013

To  
Kora Sai Prasanna Subbalakshmi  
కోర సాయి ప్రసన్న సుబ్బలక్ష్మి  
W/O: Kora Veera Venkata Sathyanarayana Murthy  
3-6-415/A/G1  
Street no 3  
Near TTD Temple  
Himayathnagar  
Himayathnagar  
Himayathnagar, Hyderabad  
Andhra Pradesh - 500029  
7382664494



KL009513152FT

951315



మీ ఆధార్ సంఖ్య / Your Aadhaar No. :

**6155 7065 0391**

ఆధార్ - సామాన్యని హక్కు



భారత ప్రభుత్వం

Government of India

కోర సాయి ప్రసన్న సుబ్బలక్ష్మి  
Kora Sai Prasanna Subbalakshmi



పుట్టిన సంవత్సరం / Year of Birth: 1969  
స్త్రీ / Female

**6155 7065 0391**



ఆధార్ - సామాన్యని హక్కు



భారత ప్రభుత్వము  
Government of India

భారత విశిష్ట గుర్తింపు ప్రాధికార సంస్థ  
Unique Identification Authority of India


నమోదు సంఖ్య / Enrollment No. : 2081/40007/54080

To  
Veeravenkata Satyanarayanamurthy Kora  
వీరవెంకట సత్యనారాయణమూర్తి కోర  
S/O: Kora Sree Ramulu,  
3-6-415/A/G1,  
Street no 3,  
Near TTD Temple,  
Himayathnagar,  
VTC: Himayathnagar, PO: Himayathnagar,  
Sub District: Himayathnagar, District: Hyderabad,  
State: Telangana, PIN Code: 500029.  
Mobile: 8919379347

38537166



KC385371665FL



మీ ఆధార్ సంఖ్య / Your Aadhaar No. :

**8761 4006 2151**


నా ఆధార్, నా గుర్తింపు



భారత ప్రభుత్వము  
Government of India



Issue Date: 12/04/2013



వీరవెంకట సత్యనారాయణమూర్తి కోర  
Veeravenkata Satyanarayanamurthy Kora  
పుట్టిన తేదీ / DOB: 15/10/1961  
పురుషుడు / Male

**8761 4006 2151**

నా ఆధార్, నా గుర్తింపు

स्थायी लेखा संख्या

/PERMANENT ACCOUNT NUMBER

ADOPK7093C

नाम /NAME

VEERAVENKATA

SATYANARAYANAMURTHY KO. RA

पिता का नाम /FATHER'S NAME

SRIRAMULU

जन्म तिथि /DATE OF BIRTH

15-10-1961



हस्ताक्षर /SIGNATURE

A handwritten signature in dark ink, appearing to read 'S. Satyanarayana Murthy', enclosed within a rectangular box.

मुख्य आयकर अधिकारी, आंध्र प्रदेश

Chief Commissioner of Income-tax, Andhra Pradesh

OUT PATIENT CARD CUM RECEIPT



UHID : HNH-00015708  
Patient Name : Mrs K SAI PRASANNA SUBBALAKSHMI  
DOB/Age/Gender : 26-Jan-1969/ 57Y 4M 10D / Female  
Doctor Reg :  
Appt Type : Follow-Up Visit / Physical  
: SELFPAY

Bill No : OCS26-00118413 Bill amount : 0.0 Rs  
Bill Date : 05-06-2026 11:59:28 AM  
Doctor Name : Dr. RAJANI KUMARI  
Department : OBSTETRICS AND GYNECOLOGY  
Specialization : CONSULTANT GYNECOLOGIST & OBSTETRICIAN

2/6/28.

B +  
WBC + UTG +.

PC 20-24.

Bacteria +

IECG WNC.

2D Echo (10)  
HTNO, DM0, Acute, DAO.

Hypothyroid.

(Recently detected)

50 mgm on Thyrox.

Give 2 days.

CBP - Hb% 13.3 gm %

WBC (10)

Platelets Adequate.

S. creatinine 0.64.

S. ure acid 2.22  
LFT (10) except Alk Phos all slightly ↑

wt: 66.7

Bp: - 148/84.

Post menopausal (10yrs)

P<sub>2</sub>C<sub>2</sub>

Bolus FTAD

2 CB + 32 yrs.

o/e - wt 66.7.

BP - 148/84

PA - cl. (10)

Pls + Renal in Rtn.

Rajani

Rp

① - 100 Nitrostat  
100 up  
o - o.  
x 5 days.

Adm:  
HRUS both break.

- HRAy → NR.  
- HIV  $\frac{P}{D}$  } NR.

- Ant ACV. NR.

- Cardiac clearance.

- PAC.

Repair.

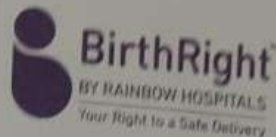Life

Plan to rep. Hyg. & BSO &  
Belue floor repair.

- PAC.

M. K. Par Pragma Subbahaiah

5744



9/6/26

To  
The Cya Repetitor  
Rainbow

B +  
Gynaecy DR.

Admit to vag. type c BLO c  
Pluc floor repair on 26/6/26

at 10.00 AM.

P2c, Boli FTMD.  
Hypotension.

Adv:

① Prepare in past.  
② NBL after 11 PM  
on 26/6/26.

③ Tel. Dulcolax  
2 tel. at BF.  
on 26/6/26.

④ Tel. Taxier - 0  
0 - 2 amp  
26/6/26

Infu.

⑤ Admit at 6 AM on  
26/6/26.



## TEST REPORT

Name : Mrs. K SAI PRASANA SUBBALAKSHMI  
Age/Gender : 57 Years/Female  
Registration ID : 260100093296  
Ref. By : Dr RAJANI KUMARI

Registered on : 05-Jun-2026 13:38  
Released on : 05-Jun-2026 16:34  
Printed on : 05-Jun-2026 16:37  
Regn Centre : Himayatnagar

### DEPARTMENT OF RADIOLOGY AND IMAGING SCIENCES HIGH RESOLUTION ULTRASOUND OF BREASTS

**History :**  
Check up.

**Technique :**  
High resolution ultrasound was performed using high frequency probe.

**Findings :**

Both breasts show predominantly fibroglandular composition.

Heterogeneous lesions noted in left breast measuring ~ 18 x 11 mm at 5 o' clock position in lower quadrant and ~ 19 x 14 mm in retroareolar region. No flow noted on color doppler.

Nipples and right retroareolar region appear normal.

No ductectasia noted.

Skin and subcutaneous tissues appear normal.

Lymph nodes with preserved fatty hilum noted in both axilla, largest measuring ~ 10 x 6 mm on right side and ~ 10 x 6 mm on left side.

**IMPRESSION :**

\* HETEROGENEOUS LESIONS NOTED IN LEFT BREAST - LIKELY FIBROADENOMA.

**BIRADS - III**

\* BILATERAL AXILLARY LYMPHNODES - NON-SPECIFIC.

ADVISED MAMMOGRAPHY CORRELATION AND FURTHER EVALUATION IF CLINICALLY INDICATED.  
- FOR CLINICAL CORRELATION.

# VIJAYA DIAGNOSTIC CENTRE®

3-6-16 & 17, Street No. 19, Opp. Lane to Tanishq, Chandra Nagar, Himayatnagar, Hyderabad - 500029

## TEST REPORT

Name : Mrs. K SAI PRASANA SUBBALAKSHMI  
Age/Gender : 57 Years/Female  
Registration ID : 260100093296  
Ref. By : Dr RAJANI KUMARI

Registered on : 05-Jun-2026 13:38  
Released on : 05-Jun-2026 16:34  
Printed on : 05-Jun-2026 16:37  
Regn Centre : Himayatnagar

### BREAST IMAGING - REPORTING & DATA SYSTEM (CLASSIFICATION)

1. Normal.
2. Benign lesion.
3. Probably benign lesion - Requires short interval follow up ultrasound.
4. Suspicious for malignancy - Requires further evaluation and biopsy correlation
5. Highly suggestive of malignancy.

----- End of Report -----



MIS-2021-0130

**DR. APOORVA CHINTAMADAKA**  
MBBS, DMRD  
Registration No:80733



# SL Diagnostics

An ISO 9001 : 2008 Certified Centre

Ground Floor, Windsor Plaza, Nallakunta, Hyd- 44.

e-mail : sldpl@yahoo.co.in, Website: www.sldiagnostics.com

**Patient Name :** Mrs. KAVITHA M 42 Y O D / F

**Patient ID :** 0100671832

**SID No. :** 01012920

**Ref By. :** Dr. SHANTHI A (SL DIAGNOSTICS)



Register Date Time : 21/05/2026

Sample Collected Date Time : 21/05/2026

Report Date Time : 22/05/2026

## UltraSound

### ULTRASOUND SCAN ABD+PELVIS

**HISTORY :** ROUTINE SCAN.

**TECHNIQUE -** REAL TIME ULTRASONOGRAPHY OF ABDOMEN PERFORMED

WITH 2-5 MHZ TRANSDUCER ON PHILIPS HD 11 X E / AFFINITI 70 G ULTRASOUND MACHINE

**Liver :** Normal in size with normal in echopattern. No evidence of mass lesion. No evidence of Intrahepatic biliary dilatation. Portal vein and CBD are normal.

**Gall bladder :** Well distended. No evidence of mass lesion. No evidence of calculi.

**Spleen :** Normal in size with normal echopattern. No evidence of mass lesion.

**Pancreas :** Normal in size, shape and echopattern. Pancreatic duct normal.

**Right kidney :** Measures 92 x 38 mm. Normal in size with normal echopattern. Pelvicalyceal system normal. Cortico medullary differentiation well maintained. No evidence of calculi.

**Left kidney :** Measures 91 x 39 mm. Normal in size with normal echopattern. Pelvicalyceal system normal. Cortico medullary differentiation well maintained. No evidence of calculi.



**Urinary bladder:** Well distended. Bladder walls normal. No evidence of calculi.

Prevoid : 200 cc

PVRU : 10 cc

**Uterus :** Anteverted, Mildly Bulky in size with normal echopattern. Measuring 89 x 44 x 50 mm.

**Posterior subserosal fibroid (12 x 9 mm) & anterior myometrial fibroid (10 x 7 mm) noted.**

Endometrium thickness 6 mm.

**Both ovaries :** Normal in size and echopattern.

Right ovary measuring 30 x 16 mm.

① T. Dulio 107

2 at 10000M.

○ NBH - 12 AM =

- Liquid dot on 11/8/2020.  
after B/F.

*[Signature]*  
Newman