



**Star Health and Allied Insurance
Company Limited**
Customer Identity Card

Policy No : 6261112105056188

| Name | DOB | Gender | Customer id |
|-----------------------|-------------|--------|-------------|
| KANDUKURI VINOD KUMAR | 05-Mar-1993 | Male | 18731491-1 |
| KEERTHI MAYI BHANURI | 03-May-1996 | Female | 18731491-2 |

Valid From : 03-Nov-2025

Valid Till : 02-Nov-2026

Office Code : 131140

Agent/Broker/TE Code : BA0000271283

TA/SSM/SM Code : SH51974

IRDAI Regn.No:129

Emergency Help Line No.1800 425 2255/1800 102 4477

e-mail : support@starhealth.in Website : www.starhealth.in

Please quote the Customer Id No. for assistance

- This ID Card is invalid,if the insurance cover is not in force.
- Immediate Intimation to 'Star' through above Tel Nos. is a must in case of Hospitalisation.

At the time of hospitalisation,kindly submit any **Government approved photo ID Card.**

Corporate Identity Number : L66010TN2005PLC056649



భారత విశిష్ట గుర్తింపు ప్రాధికార సంస్థ
భారత ప్రభుత్వం
Unique Identification Authority of India
Government of India


రిజిస్ట్రేషన్/ Enrolment No.: 2189/64084/80605

Download Date: 02/04/2018

Generation Date: 16/08/2017

To
 శ్రీ కృష్ణ మయీ భానురి
 Keerthi Mayi Bhanuri
 D/O Krishna Kumar Bhanuri
 37-89
 Jagathgiri Nagar
 Jagathgiri Gutta
 Near Last Bus Stop
 Balanagar
 Balanagar Township
 K.v. Rangareddy Telangana - 500037
 9618773940

Signature Not Verified
 INDIA IDENTIFICATION AUTHORITY
 Date: 02/04/2018 09:06:51
 127



QR Code with Photograph

మీ ఆధార్ సంఖ్య / Your Aadhaar No. :
6151 7373 5103
 నా ఆధార్, నా గుర్తింపు



భారత ప్రభుత్వం
Government of India



శ్రీ కృష్ణ మయీ భానురి
 Keerthi Mayi Bhanuri
 పుట్టిన తేదీ/DOB: 03/05/1996
 లింగం/ GENDER: FEMALE



6151 7373 5103

నా ఆధార్, నా గుర్తింపు



Government of India



సమాచారం

- ఆధార్ గుర్తింపుకు ధృవీకరణ, పౌరసత్వాలకి కాదు.
- గుర్తింపుకు ధృవీకరణ ఆన్‌లైన్ ఆథెంటికేషన్ ద్వారా పొందవచ్చు.
- ఇది ఎలక్ట్రానిక్ పద్ధతిలో వ్రాయబడిన లేఖ.

INFORMATION

- **Aadhaar** is a proof of identity, not of citizenship.
- To establish identity, authenticate online.
- This is electronically generated letter.


- ఆధార్ దేశమంతటా ఆమోదించబడుతుంది.
- ఆధార్ బహిష్కరణలో ప్రభుత్వ మరియు ప్రభుత్వతర సేవలు అందచేయడంలో సహాయ పడుతుంది.
- **Aadhaar** is valid throughout the country.
- **Aadhaar** will be helpful in availing Government and Non-Government services in future.



భారత విశిష్ట గుర్తింపు ప్రాధికార సంస్థ
Unique Identification Authority of India

బిరుదావా:
 D/O కృష్ణ కుమార్ భానురి, 37-89, జగథగిరి నగర్,
 జగథగిరి గుట్టా, లాస్ట్ బస్ స్టాప్ దగ్గర, బాలానగర్, కె.వి.రంగారెడ్డి,
 తెలంగాణ - 500037

Address:
 D/O Krishna Kumar Bhanuri, 37-89,
 Jagathgiri Nagar, Jagathgiri Gutta, Near Last
 Bus Stop, Balanagar, K.v. Rangareddy,
 Telangana - 500037




QR Code with Photograph

6151 7373 5103



భారత ప్రభుత్వం
 Government of India

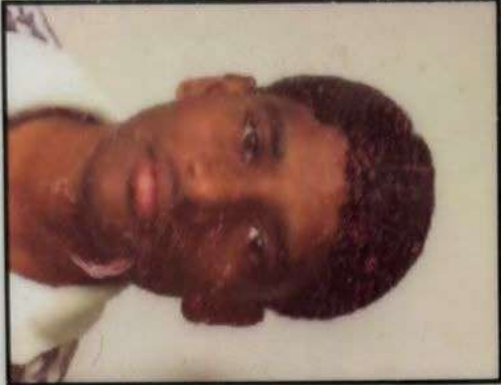

భారత విశిష్ట గుర్తింపు ప్రాధికార సంస్థ
 Unique Identification Authority of India



भारत सरकार

GOVERNMENT OF INDIA



Kandukuri Vinod

Kumar

DOB: 05/03/1993

MALE

5387 7673 2829



నా ఆధార్ - నా గుర్తింపు



भारतीय विशिष्ट पहचान प्राधिकरण
UNIQUE IDENTIFICATION AUTHORITY OF INDIA

Address

S/O Kandukuri Venkateshwarulu, H No
2-20-5/3/17/1, Sai Ram Nagar Colony,,
Chilkanagar Road, Uppal, K.V.
Rangareddy,
Telangana - 500039



1947
1800 300 1947



help@uidai.gov.in

WWW

www.uidai.gov.in

P.O. Box No. 1947,
Bengaluru-560 001

आयकर विभाग

INCOME TAX DEPARTMENT



भारत सरकार

GOVT. OF INDIA

KANDUKURI VINOD KUMAR

VENKATESHWARULU KANDUKURI

05/03/1993

Permanent Account Number

EIDPK0349M

K. Vinod


Signature





Fetal Medicine Report

RAINBOW HOSPITAL FOR WOMEN AND CHILDREN
 3/6/234, Old MLA Quarters Rd.
 Himayatnagar, Hyderabad -500029
 T - 040-48873000
 Reg No (Under PC & PNDT Act 1994): 0116A1466/2023



FetalMedicine ID:
 HNR2816686
 ViewPoint ID: 2816686
 Date 19-06-2026

Growth Scan

RAINBOW HOSPITAL FOR WOMEN AND CHILDREN
 3/6/234, Old MLA Quarters Rd.
 Himayatnagar, Hyderabad -500029
 T - 040-48873000
 Reg No (Under PC & PNDT Act 1994): 0116A1466/2023

Patient: **Bhanuri Keerthi. Mayi** DOB: 03-05-1996
 5000039, uppal, hyd
 Exam date: 19-06-2026

Indication Fetal growth scan

History **General** Smoking: no. Height 155 cm, 5 ft 1 in
History
OB History Gravida 1

Method Transabdominal ultrasound examination, Voluson E8. View: Suboptimal view: limited by late gestational age

Pregnancy Singleton pregnancy. Number of fetuses: 1

| Dating | Date | Details | Gest. age | EDD |
|---------------|------------------|---------|------------|------------|
| LMP | 10-10-2025 | | 36 w + 0 d | 17-07-2026 |
| Agreed dating | based on the LMP | | 36 w + 0 d | 17-07-2026 |

General Evaluation Cardiac activity present. FHR 150 bpm. Fetal movements: visualised. Presentation: cephalic
Placenta: posterior high
Umbilical cord: 3 vessel cord
Amniotic fluid: Amount of AF: normal. Largest pool 5.9 cm. AFI 9.0 cm

| Fetal Biometry | Measurement | Value | Percentile | Measurement | Value | Percentile |
|----------------|---------------|----------|------------|-------------|----------|------------|
| Fetal Biometry | BPD | 90.7 mm | 95% | TAD | 93.6 mm | |
| | OFD | 104.2 mm | 2% | AC | 298.5 mm | 8% |
| | HC | 306.5 mm | 10% | Femur | 70.8 mm | 53% |
| | Cerebellum tr | 45.5 mm | 91% | Humerus | 61.7 mm | 61% |
| | APAD | 96.4 mm | | HC / AC | 1.03 | |

Fetal Weight Calculation:

| | | | | |
|-------------|-----------|-----|--------|------------------------|
| EFW | 2,527 g | 22% | EFW by | Hadlock (BPD-HC-AC-FL) |
| EFW (lb,oz) | 5 lb 9 oz | | | |

Head / Face / Neck Biometry:

| | | | | |
|-----------|--------|-----|-----------|--------|
| BPD / OFD | 0.87 | 94% | 2nd Ventr | 4.5 mm |
| 1st Ventr | 2.7 mm | | | |

Abdomen Biometry:

| | | | | |
|------------|----------------------|------------|----------------------|-----|
| MAD | 95.0 mm | Trunk area | 90.2 cm ² | 91% |
| Trunk area | 70.9 cm ² | | 39% | |

Rainbow Children's Medicare Limited

ell.

Urinary Tract Biometry:

| | | | |
|--------------------|--------|--------------------|--------|
| Rt Renal pelvis ap | 3.2 mm | Lt Renal pelvis ap | 2.7 mm |
|--------------------|--------|--------------------|--------|

Extremities / Bony Structures Biometry:



| | | | |
|----------|------|---------|------|
| FL / BPD | 0.78 | FL / AC | 0.24 |
| FL / HC | 0.23 | | |

Fetal Doppler

Umbilical Artery:

| | | | | | | | |
|----|------|---|-----|----|------|---|-----|
| PI | 0.67 |  | 15% | RI | 0.51 |  | 21% |
|----|------|---|-----|----|------|---|-----|

Mid Cerebral Artery:

| | | | | | | | |
|----|------------|---|-----|--------|----------|---|-----|
| PI | 1.82 |  | 54% | PS | 0.77 MoM | | |
| PS | 41.00 cm/s | | | CPR PI | 2.72 |  | 79% |

Maternal Doppler

Right uterine artery:

| | | | | | | | |
|----|------|---|-----|----|------|--|--|
| PI | 0.70 |  | 55% | RI | 0.50 | | |
|----|------|---|-----|----|------|--|--|

Left uterine artery:

| | | | | | | | |
|----|------|---|-----|----|------|--|--|
| PI | 0.71 |  | 57% | RI | 0.47 | | |
|----|------|---|-----|----|------|--|--|

| | | | | | | | |
|----------------|------|---|-----|--|--|--|--|
| Mean PI | 0.71 |  | 56% | | | | |
|----------------|------|---|-----|--|--|--|--|

Comment

Please note: All fetal anomalies cannot be detected by ultrasound alone. The pick up rate of abnormalities depend on gestational age of the fetus, fetal position, maternal habitus, tissue penetration of ultrasound waves and machine resolution. The results of the today's scan have been discussed with the parents. They were aware that ultrasound examination alone cannot exclude all genetic syndromes or chromosomal abnormalities. This report is not for medicolegal purposes.

Impression

Steroid covered

GDM on diet

There is a single viable intrauterine pregnancy.

The fetus is in cephalic presentation today .

Fetal growth, (EFW - 22 nd centile)

Amniotic fluid (AFI - 9.0) is normal (10 th centile)

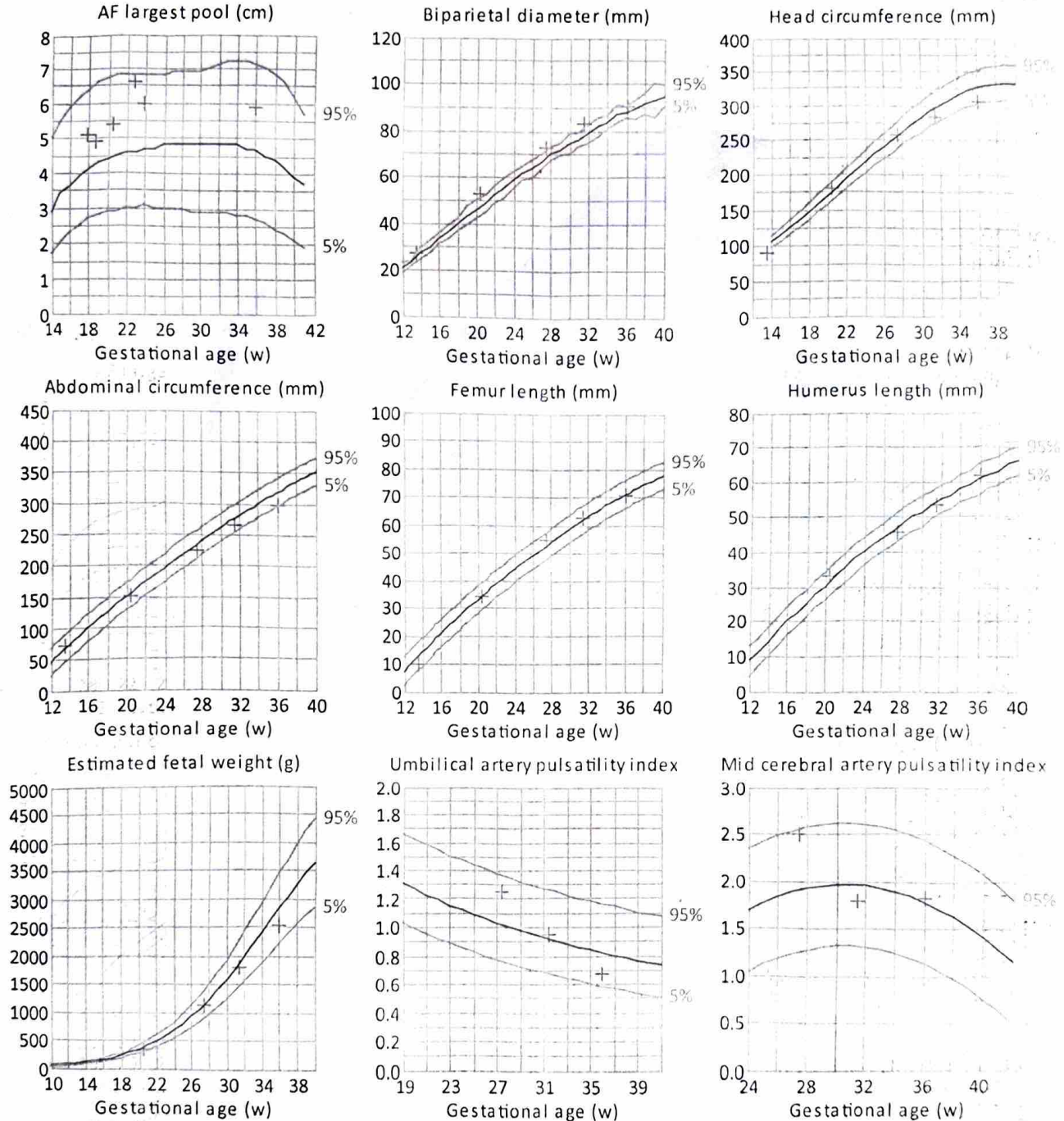
Fetal Doppler and Uterine artery Doppler are normal.

Please note : There can be a disparity in estimated fetal weight and actual birthweight of the baby of about 15-20 % due to advance gestational age and fetal position. Please correlate clinically .

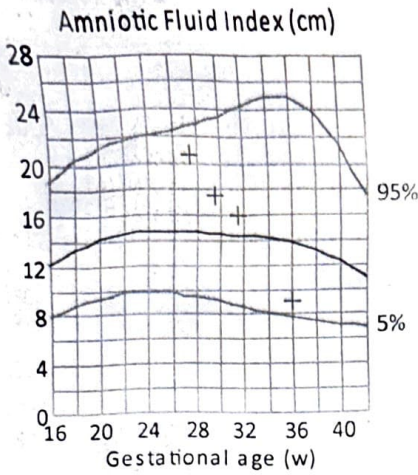
Detailed structural evaluation of fetus not possible due to advanced gestation and fetal position. All abnormalities cannot be excluded by ultrasound alone. Some abnormalities evolve as gestational age advances.

I, Dr. Mythreyi. K declare that while conducting ultrasonography / image scanning on Mrs. Keerthi, I have neither detected nor disclosed the sex of her fetus to any body in any manner.

Follow-up Rescan after 1 week for AFI scan (26 th June 2026)



Medicine Report



Dr. Padmaja. Y
Regd. No -
52427
Referring
Consultant

Dr Mythreyi K

Performing Physician

