



Date: 10-06-2026 06:53:00 PM

To,

Rainbow Childrens Hospital Vikrampur

OPP NEW KARKHANA POLICE STATION H.NO. 3-7-222 AND 3-7-223,SY NO 51 TO 54, KARKHANA MAIN ROAD KAKAGUDA

City :Secunderabad

State :500009

Fax : 23397476

CLAIM ID : 1912617
 PATIENT NAME : YAMINI P
 EMPLOYEE NAME: YAMINI P
 EMPLOYEE NO : 520896
 POLICY HOLDER : ADP PVT LTD

SUBJECT: Additional Information Request

Dear Sir /Madam,

With response to your requisition for offering CASHLESS hospitalisation to the mentioned patient , we would require the following information to ascertain the coverage for the patient.


| Query Reason | Description |
|---------------------------|---|
| Obstetrics and gynecology | History of taking abortive pills or provide cause for current ailment |
| Surgical management | Confirmed diagnosis with supporting investigation report USG |
| Surgical management | Exact name of the surgical procedure to be done. |

We request you to submit the above information on Hospital/ Doctor's letterhead by Treating Doctor in the next 24 hours or before discharge, whichever is earlier, else the same will be considered 'Denied for CASHLESS Benefits'.

Thanks & Regards,

Tel No.: 1800202030
 E-mail: support@volohealthtpa.com

Volo Health Insurance TPA Pvt Ltd (Formerly known as East West Assist Insurance TPA Pvt Ltd)



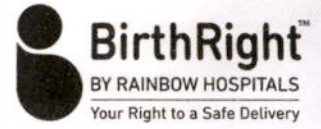
Rainbow Children's Medicare Ltd.

3-7-222 & 3-7-223, Sy. No. 51 & 54, Opp. New Karkhana Police Station
Karkhana Main Road, Kakaguda, Secunderabad - 500009.

Tel : +91-40-4246 2200, 2789 5050, 2789 6060.

GST: 36AABCR4014M1ZE email: vrchbilling@rainbowhospitals.in

CIN: L85110TG1998PLC029914 www.rainbowhospitals.in



To whomsoever it concern

Patient name Yashini P

• VEN - 205777

Diagnosed - Primic with 14+4 weeks
came to clo preterm premature rupture of
membrane & APH & inevitable abortion

Patient was having severe oligohydramnios
& active leak, AFI < 1cm, they were given
option for termination of pregnancy





PLEASE SCAN QR CODE

Name : Mrs. YAMINI
Age/Gender : 26Y(s) /Female
Ref By : DR MRIDULA VERMA
Reg.No : 26ASRP0007478

TID : UMR4624885
Registered On : 26-May-2026 07:20 PM
Reported On : 26-May-2026 08:02 PM

DEPARTMENT OF ULTRASOUND
Ultrasound NT Scan

LMP: 28/02/2026

GA by LMP: 12 weeks 3 days

EDD by LMP : 07/12/2026

GA (Assigned as per CRL) : 12 weeks 3 days

Scan EDD : 05/12/2026

Uterus is gravid.

A single live intrauterine gestation is seen.

Fetal movements and cardiac activity appears normal

CRL measures 5.99 mm which corresponds to 12 weeks 3 days.

Fetal cardiac pulsations are seen (FHR- 158 bpm).

Liquor : Adequate

Nasal bones visualized

Nuchal translucency: 1.4 mm.

Placenta formation - Developing anteriorly, Grade '0' maturity.

No tricuspid regurgitation

No reversal of 'A' wave in ductus venosus

Internal Os is closed.

Cervical length: 3.8 cm.

No free fluid in the pouch of Douglas.



PLEASE SCAN QR CODE

Name : Mrs . YAMINI
Age/Gender : 26Y(s) /Female
Ref By : DR MRIDULA VERMA
Reg.No : 26ASRP0007478

TID : UMR4624885
Registered On : 26-May-2026 07:20 PM
Reported On : 26-May-2026 08:02 PM

IMPRESSION:

* Present scan reveals single live intrauterine pregnancy corresponding to a gestational age of 12 weeks 3 days

* Normal Nuchal translucency thickness.

- Suggested clinical correlation & follow up.

*** End Of Report ***

Typed By: jprasanna

Dr P Latha Sree
Consultant Radiologist