

Fetal Medicine Report



RAINBOW HOSPITAL FOR WOMEN AND CHILDREN
 3/6/234, Old MLA Quarters Rd.
 Himayatnagar, Hyderabad -500029
 T - 040-48873000
 Reg No (Under PC & PNDT Act 1994): 0116A1466/2023

FetalMedicine ID:
 HNR1931734
 ViewPoint ID: 1931734
 Date 16-06-2026

Growth Scan

RAINBOW HOSPITAL
 3/6/234, Old MLA

Patient: **Thakur Kajal** DOB: 31-01-1994
 T - 040-48873000 17-1-386/1/A/5/92, Kashan nagar colony, Saidabad, 8121445508
 Exam date: 16-06-2026

Indication Fetal growth scan

History
General Blood group: B, Rh positive. Smoking: no. Height 156 cm, 5 ft 1 in
History nonconsanguineous couple, spontaneous conception
OB History **Gravida 4. Para 1**
 1. spontaneous miscarriage. Gest. age 18 w + 0 d. Details: DCDA twins, Cervical incompetence
 2. live birth. Gest. age 34 w + 0 d. Weight 2,600 g. Details: SVB. McDonald cerclage. H/o PE, GDM
 3. TOP. Gest. age 17 w + 0 d. Details: DCDA Twins, PPRM

Method Transabdominal ultrasound examination, Voluson E8. View: Suboptimal view: limited by late gestational age

Pregnancy Singleton pregnancy. Number of fetuses: 1

Dating	Date	Details	Gest. age	EDD
LMP	06-10-2025		36 w + 1 d	13-07-2026
Agreed dating	based on the LMP		36 w + 1 d	13-07-2026

General Evaluation
Cardiac activity present. FHR 146 bpm. **Fetal movements:** visualised. **Presentation:** cephalic
Placenta: posterior high
Umbilical cord: 3 vessel cord
Amniotic fluid: Amount of AF: normal. AFI 20.0 cm

Fetal Biometry	Measurement	Value	Percentile	Measurement	Value	Percentile
BPD	96.7 mm	96.7	>99%	TAD	100.2 mm	
OFD	112.2 mm	112.2	26%	AC	316.0 mm	43%
HC	328.6 mm	328.6	58%	Femur	71.3 mm	56%
Cerebel-lum tr	46.7 mm	46.7	96%	Humerus	60.5 mm	41%
APAD	101.0 mm	101.0		HC / AC	1.04	26

Fetal Weight Calculation:

EFW	2,932 g	59%	EFW by Hadlock (BPD-HC-AC-FL)
EFW (lb,oz)	6 lb 7 oz		

Head / Face / Neck Biometry

Rainbow Children's Medicare Limited

Fetal Medicine Report

BPD / OFD 0.86  90% 2nd Ventr
1st Ventr 4.8 mm

4.5 mm

Abdomen Biometry:

MAD 100.6 mm
Trunk area 79.5 cm²  75% Trunk area 101.2 cm²  >99%
rect.

Urinary Tract Biometry:

Rt Renal pelvis ap 2.3 mm Lt Renal pelvis ap 2.1 mm

Extremities / Bony Structures Biometry:

FL / BPD 0.74 FL / AC 0.23
FL / HC 0.22

Fetal Doppler

Umbilical Artery:

PI 0.95  74% RI 0.63  76%

Mid Cerebral Artery:

PI 1.76  49% PS 1.02 MoM
PS 55.00 cm/s CPR PI 1.85  18%

Maternal Doppler

Right uterine artery:

PI 0.48  5% RI 0.36

Left uterine artery:

PI 0.70  55% RI 0.47
Mean PI 0.59  23%

Comment

Please note: All fetal anomalies cannot be detected by ultrasound alone. The pick up rate of abnormalities depend on gestational age of the fetus, fetal position, maternal habitus, tissue penetration of ultrasound waves and machine resolution. The results of the today's scan have been discussed with the parents. They were aware that ultrasound examination alone cannot exclude all genetic syndromes or chromosomal abnormalities. This report is not for medicolegal purposes.

Impression

PGDM on Insulin and OHA

There is a single viable intrauterine pregnancy.

The fetus is in cephalic presentation today

Fetal growth, (EFW - 59 th centile)

Amniotic fluid (AFI - 20.0) - is normal (82 nd centile)

Fetal Doppler and Uterine artery Doppler are normal.

Please note : There can be a disparity in estimated fetal weight and actual birthweight of the baby of about 15-20 % due to advance gestational age and fetal position. Please correlate clinically .

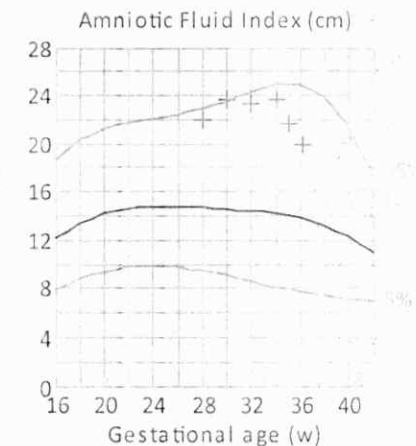
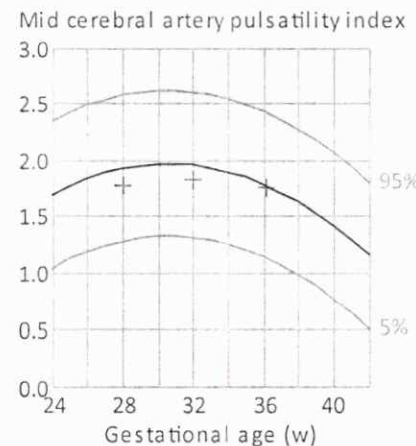
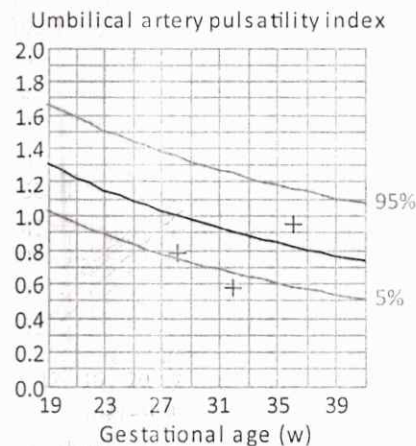
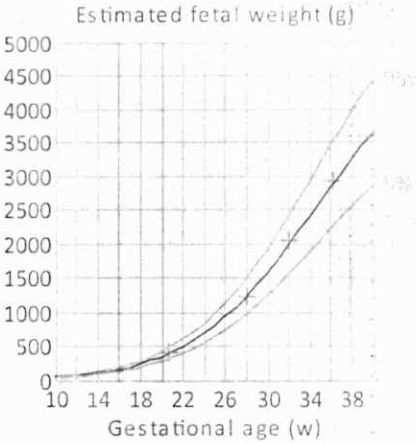
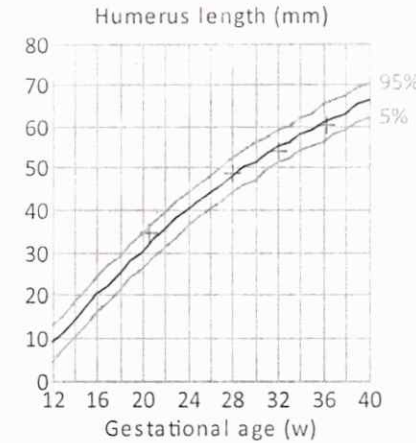
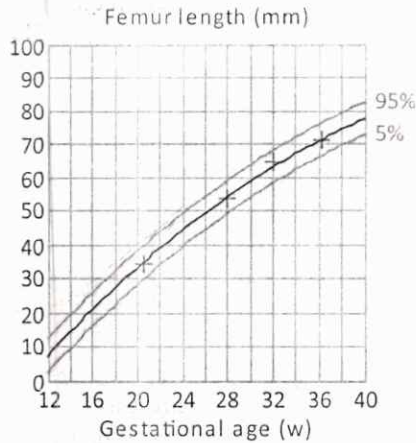
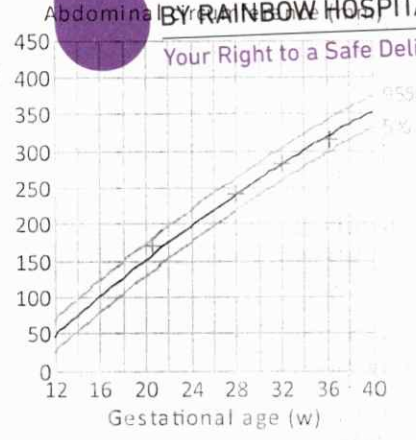
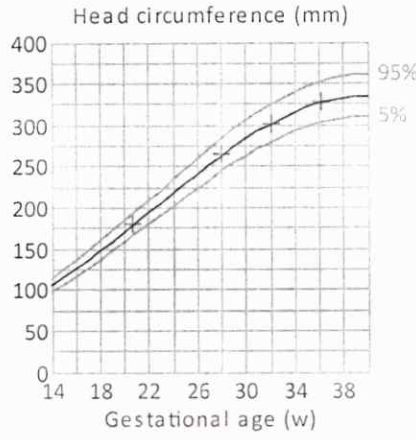
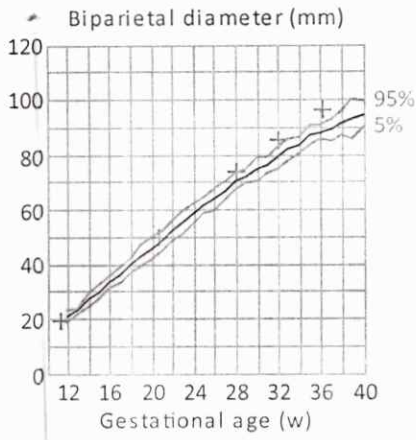
Detailed structural evaluation of fetus not possible due to advanced gestation and fetal position. All abnormalities cannot be excluded by ultrasound alone. Some abnormalities evolve as gestational age advances.

I, Dr. Mythreyi. K declare that while conducting ultrasonography / image scanning on Mrs. Kajal, I have neither detected nor disclosed the sex of her fetus to any body in any manner.

Follow-up

Follow-up as clinically indicated

Fetal Medicine Report



Dr. Padmaja. Y
 Regd. No -
 52427
 Referring
 Consultant

Dr Mythreyi K

Performing Physician

